



# **Transaxillary Breast Augmentation/Wise-Pattern Mastopexy in the Massive Weight Loss Patient**

**George Bitar, MD, FACS**



# Transaxillary Breast Augmentation/ Wise-Pattern Mastopexy in the Massive Weight Loss Patient

70

George John Bitar

## 70.1 Introduction

For obese women, losing a lot of weight is a great achievement as it requires willpower, determination, and sacrifice. Women can either undergo massive weight loss (MWL) by dieting and exercising or via bariatric surgery such as laparoscopic banding or gastric bypass surgery. MWL after a bariatric procedure requires about a year to 18 months. Changes occur in the process of weight loss with respect to family dynamics, romantic relationships, social interactions, work habits, self-esteem, and other life issues that may be unique to each individual patient. Ideally, plastic surgery on MWL patients provides enormously positive results for their self-image, self-esteem, attitude, and – ultimately – their health.

There is disappointment after the MWL because instead of having a fabulous, sexy body as part of those welcome changes, a woman usually ends up with a lot of excess unwanted skin. A typical MWL female patient can go from having macromastia to significantly ptotic, empty breasts. The most effective answer to improve the volume and shape of the postweight loss breasts is a breast augmentation/mastopexy.

## 70.2 Initial Consultation

Preparation for plastic surgery after MWL must be very carefully undertaken, from choosing the right board-certified plastic surgeon and discussing the

procedures at length, to having a very good knowledge of the perioperative care and requirements [1]. A plastic surgeon has to be clear about what can be realistically and safely achieved via plastic surgery, in what time frame, and with what potential complications. Sometimes a long-term plan is discussed to address multiple areas with which a patient is not happy. For example, the decision can be made to proceed with performing an abdominoplasty and brachioplasties in an initial operation, wait a year, and then perform the thigh plasties and mastopexies/breast augmentations. This is a common and realistic scenario because it addresses multiple areas to be improved in a safe approach in patients with a high rate of complications. In one study of postbariatric plastic surgery, complications relating to wound problems were noted in 66% of patients [2].

The medical history is reviewed, a physical exam performed, and the patient is also asked to get medical clearance from her own physician, as well as basic labs, to ensure that the patient will undergo the procedure safely. The patient should have the opportunity to discuss the procedure with an experienced nurse, the plastic surgeon who will perform the procedure, and to talk to patients who have had the same procedure performed by the same surgeon.

## 70.3 Breast Evaluation for Cosmetic Surgery After Massive Weight Loss

It is important for a patient to understand what a breast augmentation, a mastopexy, is, and what a breast augmentation/mastopexy will accomplish. Different techniques, limitations, risks, benefits, and postoperative expectations should be discussed in detail. Because a

---

G. J. Bitar  
Bitar Cosmetic Surgery Institute, 8650 Sudley Rd. #203,  
Manassas, VA 20110, USA  
e-mail: georgebitar@drbitar.com

woman may end up with unsightly scars as well as a long-term prosthesis in her breasts, it is important to discuss long-term consequences.

A woman who has undergone MWL may have enough breast tissue to make her a good candidate for a mastopexy, with or without augmentation. The surgeon needs to address what would be the most appropriate mastopexy in her case and what is the best augmentation procedure, and, a myriad of choices have to be made. The best approach is to offer the patient the choices, but guide them in the direction that is optimal.

#### 70.4 Augmentation, Mastopexy, or Both?

The decision to have a breast augmentation, mastopexy, or mastopexy-augmentation may not be as straightforward as it would seem. Every plastic surgeon handles the situation a little differently. One way to address it is by asking the patient what bothers them about their breasts. If the size is too small, then an augmentation is sufficient. If they are not happy with the ptosis, but are happy with the size, then a mastopexy is appropriate. If they are not happy with the ptosis and the size, then a mastopexy and augmentation is in order (Fig. 70.1). Sometimes, the lines are not clearly drawn.

If a patient has mild ptosis, but their main complaint is hypomastia, then it is a judgment call as to whether a mastopexy should be performed with an augmentation, or to wait a year and maybe the breast will settle nicely, thus avoiding a mastopexy. If a patient has ptosis and a decent sized breast, then they may be happy with just a mastopexy, as opposed to a mastopexy/augmentation. These options and the possibility of requiring future surgery should be discussed thoroughly with the patient.

#### 70.5 Mastopexy Techniques

Differing views on what is the optimal mastopexy are certainly not in shortage! With MWL patients, the typical presentation is that of a woman with a wide chest circumference, long inframammary fold extending sometimes to the back, suboptimal skin quality with striae, laxity of muscles and skin, with varying fat volume and severe

ptosis. Because of this typical anatomical presentation, a minimal lift that may offer some benefit in women with mild ptosis such as a crescent mastopexy or a Benelli mastopexy, will fall short of achieving a long-term desirable result either due to the nipple-areolar complex (NAC) stretching, distorting, the breast bottoming out, or because of not achieving enough lift.

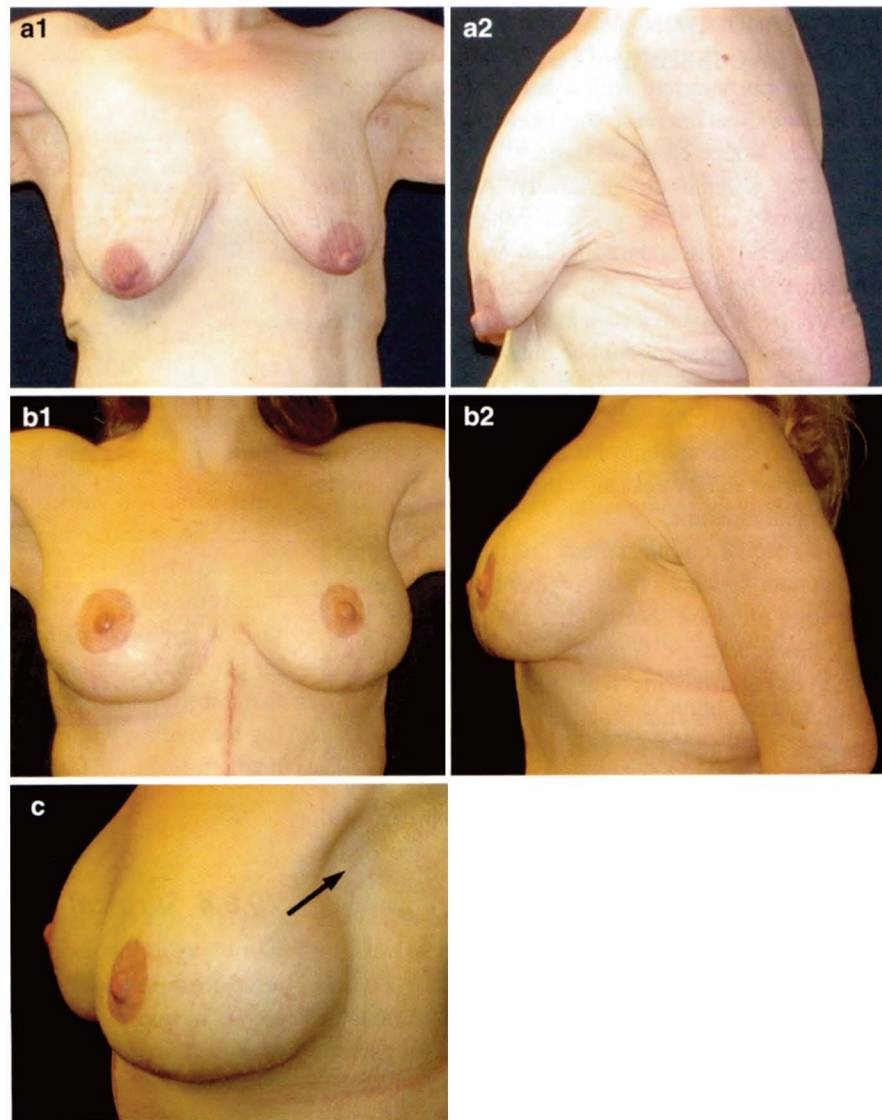
A Wise pattern mastopexy with an inferior pedicle and anchor lift incision technique is a reliable technique, provided appropriate dissection is undertaken and enough of a lift is achieved to minimize the “bottoming out” effect. The reason for that choice is that in a MWL patient, this technique addresses and corrects the anatomical problems listed above. Variations of the vertical mastopexy technique, which should also be considered, are discussed elsewhere.

#### 70.6 Breast Augmentation Technique

Breast augmentation has become one of the most popular cosmetic surgery procedures in the U.S.A. with a variety of techniques with which it is performed. The literature describes the evolution of various techniques of breast implant placement in the submuscular vs. subglandular plane, silicone vs. saline implants, transaxillary vs. transumbilical, inframammary, or periareolar placement of the incision [3–5]. Even, within each technique, there is a myriad of nuances and variations between surgeons. Like everything in cosmetic surgery, a surgeon has to choose an operation that works well in his or her hands, makes the patient happy, and has a relatively low complication rate. There is no such thing as the “perfect breast augmentation technique,” and thus opinions differ and debates are heated among plastic surgeons as to what is the best way to perform a breast augmentation. I believe that the transaxillary breast augmentation with saline implants and via a blind dissection technique, i.e., without an endoscope, is a simple procedure with a high level of satisfaction and a low rate of complications.

The main indication for a breast augmentation is hypomastia or breast asymmetry or both. The decision by a woman to have a breast augmentation should be explored in the initial consultation. The best reasons to accept to perform a breast augmentation is for a woman to feel better about herself in a decision which was well thought out and arrived at without external forces. Typically, a woman like that will have the highest likelihood of success and happiness with the operation.

**Fig. 70.1 (a1,2)**  
Preoperative 38-year-old woman who had undergone a gastric bypass with resultant massive weight loss. **(b1,2)** One year postoperative after an axillary breast augmentation/mastopexy, simultaneously performed with an abdominoplasty. **(c1,2)** The *arrow* is pointing to the patient's virtually imperceptible underarm scar



Furthermore, she will be in the best position to handle a complication appropriately, should there be one.

implants achieve a very natural, long lasting result, with minimal complications.

## 70.7 Breast Augmentation in MWL Patients

In addition to the traditional debate on whether saline or silicone should be used in breast augmentation, MWL patients offer additional opportunities. Autologous breast augmentations, either with fat transfer or with the lateral breast tissue, are the options. The author has felt that a Wise pattern mastopexy with a transaxillary breast augmentation and smooth saline

## 70.8 Technical Details-Transaxillary Breast Augmentation/Wise-Pattern Mastopexy

### 70.8.1 Preoperative Work-Up

A patient should get a routine medical clearance and a psychiatric clearance when needed [6]. In case of MWL patients, a nutritional consultation is recommended due

to the advantage in outcome from cosmetic surgery when nutrition is optimized [7]. A history of medications that can interfere with a good outcome, such as medications that increase the likelihood of bleeding, should be stopped before surgery. A pregnancy test should be ordered preoperatively. Also a complete blood count and INR gives a general idea of the hematological state of the patient. A urinalysis is important, since a positive test may warrant treatment before inserting prosthesis in a patient with an ongoing infection. A mammogram should be obtained in women at a higher risk for breast cancer, based on the recommendations of the American Cancer Association. Patients should also stop smoking for at least 2 weeks prior to the operation and 2 weeks after the operation to improve the surgical outcome.

Two specific circumstances are worth mentioning. If a woman seeking breast augmentation is planning on getting pregnant shortly after the procedure, especially since bariatric surgery is being performed on women of child-bearing years, the prospective patient should understand that pregnancy can create changes in breast shape and size. Also, there is a small chance that a breast augmentation operation may have complications that can render a woman unable to breast-feed. A future operation, either to change the size of the breast implant, remove it, or perform a mastopexy, may be warranted, and a patient should be well aware of these possibilities. It is also important to address the history of breast cancer in the woman seeking a breast augmentation or in her family. Whether silicone or saline implants are placed, submuscular or subglandular, the issue of breast cancer detection should be discussed with the patient.

### **70.8.2 Surgical Marking**

The patient is marked while standing. The inframammary folds, the superior border of where the implant should lie, and the midline are marked. A 2-cm line is drawn at the lower aspect of the hair-bearing area of the axilla. A Wise pattern mastopexy is also marked initially, with the expected new location of the NAC, the amount of skin to be deepithelialized centrally, and the amount of skin to be resected both medially and laterally. Those amounts depend on the shape and size of each individual breast.

### **70.8.3 Surgical Prep**

The patient is initially given prophylactic antibiotics, DVT (deep vein thrombosis) prophylaxis, and is intubated with general anesthesia, LMA, or intravenous sedation given as a surgeon's choice. The arms of the patient are at right angle to the body and wrapped around the arm-rest. The breasts are infiltrated in a fashion similar to a liposuction area with about 75–120 mL on each side of tumescent solution for a total of 150–240 mL (500 mL of saline, 50 mL of lidocaine 1% plain, and 1 ampule of epinephrine 1:10,000). The technique with which to inject is important so as to achieve two goals: hydrodissection in the submuscular plane and vasoconstriction of the area to be dissected. A pneumothorax is much less likely if the surgeon lifts the breast with the nondominant hand and injects the tumescent fluid with the dominant hand in a fashion that is parallel to the rib cage in the submuscular plane. The patient is then prepped in a usual sterile fashion from the neck to below the umbilicus, including the axillas, while the tumescent fluid is allowed to take effect.

### **70.8.4 Surgical Technique**

After the tumescent solution takes effect, a 2-cm incision is made in the lower pole of the hair-bearing area of the axilla. With a curved Mayo scissors, a pocket is created in the axilla. Next, digital dissection is carried out to establish an intermuscular plane between the pectoralis major and minor muscles. Care is taken to avoid trauma to vessels and musculature; however, the tumescent solution helps to minimize bleeding to the point that electrocautery is seldom used with this technique, since it is almost a bloodless procedure.

When the intermuscular plane has been established, a blunt curved dissector such as a Van Buren or a uterine sound dissector is used to complete the subpectoral pocket. After the submuscular pocket is created, implant sizers are inserted through the axillary incision and are filled to the size on which the patient and the surgeon have agreed. It is important to choose a breast implant size that augments the breast in a natural way and not exceed the diameter of the breast [8]. The back of the operative table is then elevated, so that the patient

is assessed in the sitting position. Implant pocket adjustment can be accomplished by either finger dissection or blunt sound dissection until the surgeon is satisfied with the size and shape of the augmented breasts. This is probably the step where experience helps the most. Medially, the muscle should be elevated enough to create nice cleavage, but not excessively to create symmastia. Inferiorly, insufficient dissection may lead to a “high-riding” implant, and aggressive dissection may lead to a “double-bubble” sign. Laterally, the breast should have a nice fullness, but if the dissection is too aggressive, then, in the future, the patient will complain that the implant ends up in the axilla when she lies down. Proper dissection of the breast pocket may initially be learned with direct visualization by the endoscopic guided method, but once a surgeon feels comfortable with the boundaries of the dissection, a blind technique is less costly, more efficient, simpler, and – at least with comparable results, in my opinion.

### **70.8.5 Replacing the Sizers with the Real Implants**

Next, one sizer implant is removed and the surgeon changes gloves, the axillary incision site is cleaned with Betadine and the assistant places an army–navy retractor to open the pocket for the surgeon. The surgeon empties the air from the saline implant, rolls it, and inserts it through the incision without it touching the skin, and with the valve facing anteriorly. When the implant has been completely inserted, it is filled with saline to the desired amount with a one-way stop-cock closed system to ensure the sterility of the saline. The sizer in the contralateral breast is kept to ensure hemostasis until the time to place the real implant in the contralateral pocket. At that time, the sizer implant is removed, and the saline implant is placed in an identical fashion in the contralateral pocket. Then the implants and the general shape of the breast are inspected as the patient is sitting up. When the shape and size are deemed appropriate by the surgeon, the filling tubes are removed. The incisions are then closed with 3.0 Vicryl interrupted sutures for the dermis and a 4.0 Vicryl subcuticular closure is performed.

### **70.8.6 Mastopexy-Augmentation Performed Simultaneously**

If a patient wishes to have a mastopexy performed simultaneously with a breast augmentation, I prefer to perform a mastopexy–augmentation in the following way: First, a breast augmentation is performed in the way described above through an axillary approach, up to the step where the implant sizers are in place.

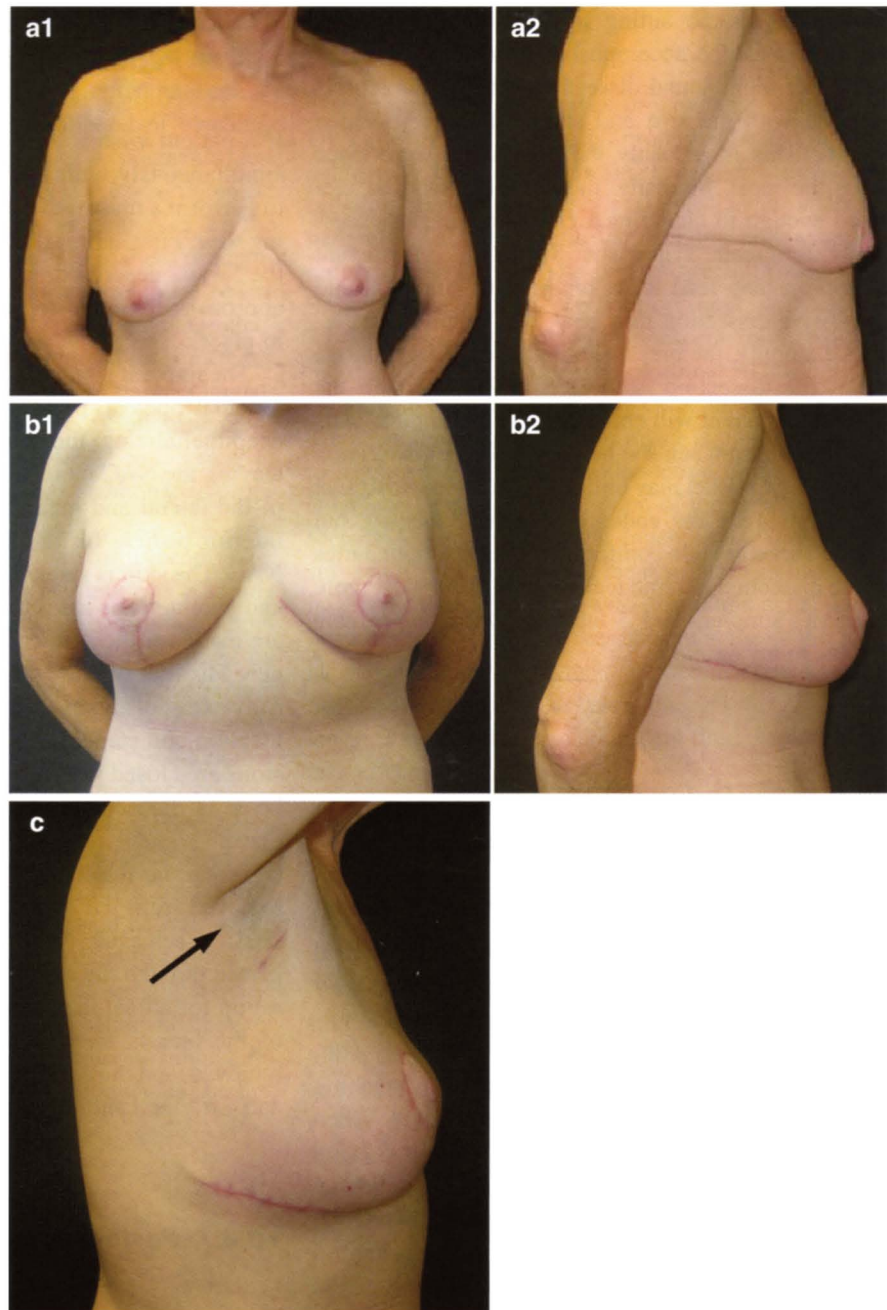
The implant sizers are left in place and a Wise pattern mastopexy is performed in the traditional way by deepithelializing the central aspect of the breast, leaving the NAC intact, and resecting the excess skin of the lateral and medial segment leaving a healthy inferior pedicle for the neurovascular supply of the NAC. The skin is stapled closed. The patient is sat up and symmetry is assessed. At this time, adjustments are made for the skin envelop if necessary. Also, the new location of the NAC is marked, the skin carefully excised, and the NAC is brought out into its new location and stapled in place. Next, the dermal incisions are closed with 3.0 Vicryl, and the subcuticular layer is closed with 4.0 Vicryl with the sizers in place.

When the mastopexy is completed, the sizers are removed from the axillary incision. Excellent hemostasis is achieved. Next, the permanent implants are placed through the axillary incision, and the patient is sat up for a final inspection. When the shape and size of the breasts are satisfactory, the filling tubes are removed, and the axillary incisions are closed with 3.0 and 4.0 Vicryl sutures.

### **70.8.7 Postoperative Care**

The incisions are covered with Steri-Strips, and foam tape is placed around the breasts to ensure healing in the proper position. The patient is then placed in a bra and dressings are placed to cover the axillary incisions. The patient is recovered in the ambulatory surgery center or hospital for an hour or two and given antiemetic medicine if needed. The patient is asked to sleep supine with the head elevated and take the appropriate antibiotic and analgesic medications.

**Fig. 70.2 (a1,2)** Preoperative 55-year-old woman. **(b1,2)** Three months postoperative after a breast augmentation/mastopexy. **(c)** Three months after surgery showing early healing results of the axillary and Wise pattern mastopexy scars. *Arrow* pointing to axillary scar

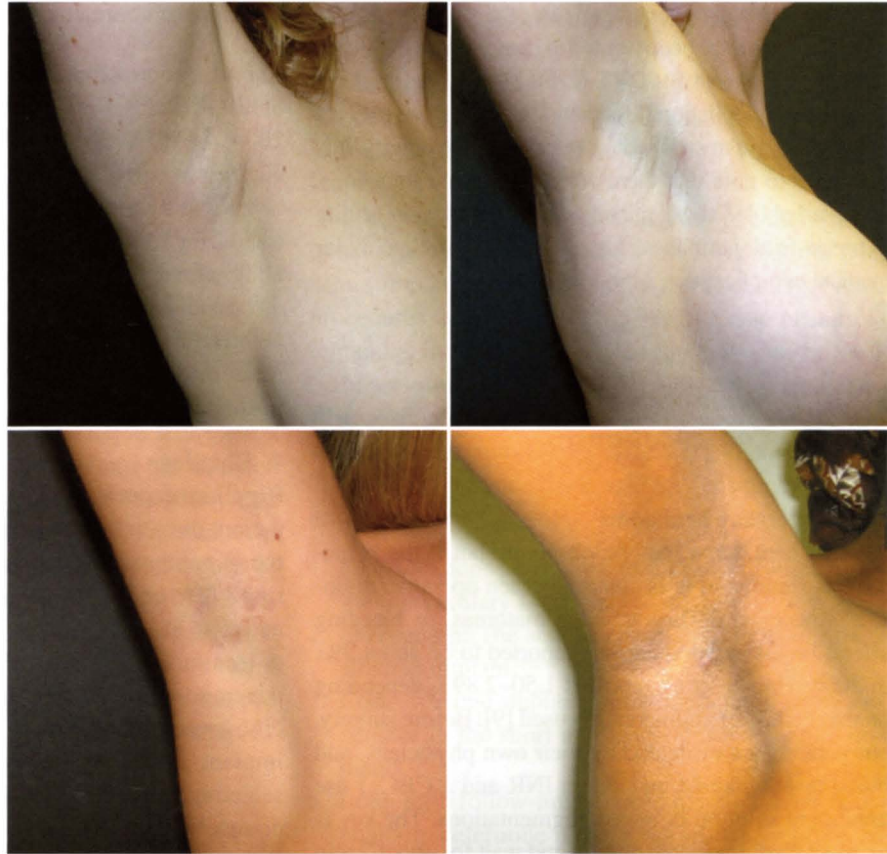


The patient is seen the following day and the incisions are inspected as well as the over-all appearance of the patient and the breasts. Any early problems are addressed in a timely fashion. Most patients heal uneventfully (Fig. 70.2) and have

mild to moderate ecchymosis and edema. The tape is removed after a week. Daily activity is resumed in a few days, work can be resumed in about a week, and exercise after the fourth week in most cases.



**Fig. 70.3** Examples of the virtually imperceptible axillary scar



### 70.9 Advantages of a Two Incision Approach for a Breast Augmentation/Mastopexy

The advantages of this technique in creating two separate surgical sites for the axillary breast augmentation and mastopexy outweigh the advantages of a “single surgical site” traditional augmentation-mastopexy with the insertion of the implants through the periareolar or anchor incision:

1. The pectoralis major muscle is minimally manipulated, since the implant is inserted in the submuscular plane, and the mastopexy is performed in the dermal and glandular planes. The dissection as such decreases postoperative inflammation and pain, also preserving intact muscle coverage for the implant, in case of an infection or dehiscence of the mastopexy anchor incision.
2. The option to adjust the implant size based on the tension on the NAC exists without difficulty, by inflating or deflating the sizer implants to achieve

the desirable volume, before committing to the final implant size.

3. There is no prolonged handling and exposure of the implant, which may decrease the chance of infection of the implant.
4. Precious intraoperative time is saved because suturing of the breast incisions can proceed faster without having to worry about puncturing the implant.

The major disadvantage of this approach is the placement of an additional axillary scar in addition to the anchor incision performed, which is usually imperceptible (Fig. 70.3) and so the patient has to consent after a thorough discussion of the available options.

### 70.10 Complications

With this technique, pain has been limited to the first few days and controlled with analgesic medications. Return to daily activity has occurred within 1 week to 10 days.

Exercise is usually encouraged after the third week. The complications have been limited to hematomas (2%), capsular contracture (4%), DVT (2%), high-riding implants (2%), implant deflation (less than 1%), and a few patients (3%) who were unsatisfied for reasons of asymmetry. It is important to note that there were no implant infections, “double-bubble” signs, pneumothorax, and loss of ability to breast-feed, permanent loss of nipple sensation, major medical complications, or mortality.

### **70.10.1 Avoidance of Common Complications:**

#### **1. Postoperative hematoma**

A small hematoma may be observed, but if the hematoma is significant or is enlarging, then operative drainage is necessary. The rate of hematomas, or bleeding after a breast augmentation is reported to be about 2%, in 2006; Handel et al. reported 1.50–2.89% depending on the method of augmentation used [9]. Before surgery, our patients are evaluated by their own physicians, and blood tests obtained include an INR and a CBC. I use tumescent solution in breast augmentations. The key is to inject the tumescent solution and wait for about 7 min to start the operation. This technique plus minimal dissection, for the breast pocket and the mastopexy flaps, gentle handling of the muscle during the procedure, and creating the appropriate pocket size for the implant, all contribute to keep the postoperative hematomas rate low, less than 1%.

#### **2. Infection**

Breast implant infections occur in general in about 1–2% of cases; a study from 2005 reports 2–2.5% [10]. The most important step in avoiding infections is to perform the surgery at a first-rate surgical facility where principles of sterility are applied regularly. Patients are given the appropriate intravenous antibiotic coverage throughout the actual surgery. I change gloves multiple times during the operation, and remain the only one who handles the implants in the operating room to ensure total sterility and avoidance of infection. After the procedure, patients are prescribed a 1-week course of antibiotics to minimize infection.

#### **3. Capsular contracture**

Capsular contracture occurs in 10–15% of women with breast implants, depending on what study is quoted. In 2004, the FDA reports a rate of 10–11%, at 5 years, for augmentation patients [11]. Capsular contractures may be caused by a subclinical infection, significant bleeding during the operation, or time and collagen remodeling alone. In the previous sections, there was a discussion about how to minimize the risk of infection or bleeding. The rate of capsular contractures in my mastopexy/breast augmentation patient population has been about 4%.

#### **4. Rippling**

Rippling, especially with saline implants, can lead to patient dissatisfaction in up to 10% of breast augmentation patients. Handel et al. also reported the rate of rippling to be 5.7–14.15% depending on the technique and type of implant used [9]. Rippling can be avoided or minimized by giving the breast implant maximum coverage with breast tissue and muscle. For that specific reason, rippling is minimized by placing an implant under the pectoralis major muscle and by selecting an implant size that would be covered almost completely by the muscle. As a result, the implant cannot be felt from the lateral edge of the breast.

#### **5. Deflation or rupture**

It is difficult to quote the rates of breast implant rupture or deflation because it is a function of time. The best way to minimize this risk is by paying attention to each step in the preoperative evaluation of a patient, the actual surgical procedure, and the follow-up care. If an implant ruptures or deflates, it needs to be exchanged.

#### **6. High riding implants**

The shape and look of the augmented breasts should be very natural. Critics have cited “high-riding” implants as a result of this technique [12]. With the use of proper surgical technique as described and good muscle dissection, the rate of high-riding implants is reduced. If that were to happen, then it is prudent to wait until about a year, when the healing has taken its course, and reoperate to fix the problem at that time.

## 70.11 Discussion

Patients who have had mastopexy/augmentations after MWL in my practice have ranged in age from 25 to 66 years. Some have had simultaneous procedures such as liposuction, abdominoplasty, or facial rejuvenation procedures. The overall satisfaction rate has been very high with a very low rate of complications.

It is critical to address the controversy of performing transaxillary breast augmentations with the “blind approach” instead of the endoscopically-assisted approach. The results of the blind approach are excellent. The critics’ view that this technique will yield a high percentage of “high-riding” implants has not been true in my breast augmentation patients. The advantages of this technique over the endoscopically-assisted technique is the shorter time in which the operation can be performed safely (the actual surgical time is 25–40 min), which is significantly less than the endoscopic approach. The second advantage is the lack of reliance on endoscopic equipment, the cost involved, and potential added variables to an operation that is otherwise very simple.

### 70.11.1 Choosing the Right Breast Implant Size

In the initial consult, the patient is asked to place a known-sized silicone breast implants in her bra and wear a shirt that would reveal her silhouette clearly. The patient tries on different size implants until she finds the size she likes. We offer our patients the option to try sizes again on a second consultation. Usually they come up with either the same size or a very close size to the one of the initial consultation. I encourage my MWL patients to choose implants in the range of 200–550 ccs, with exceptions in certain situations.

### 70.11.2 Silicone or Saline Breast Implants

The choice of implant type affects the type of surgery to be performed. It is difficult to perform a

silicone breast augmentation through an axillary approach. The incision has to be 5 cm with a silicone implant [13] instead of 2 cm with a saline implant. The technique discussed in this chapter is limited to saline implants inserted through an axillary incision.

Silicone implants are advantageous in certain situations. Silicone breast implants feel more natural than saline implants when a woman has had many breast procedures and has very little breast tissue or muscle remaining in the breast. Silicone implants may be preferable also when a woman is very thin, in which case, silicone implants may feel more natural. In these two situations, the author will offer the patients silicone breast augmentation. The advantages of saline implants are as follows:

1. Scar location: They are more easily inserted from the transaxillary incision.
2. Scar length: The scar is about 2 cm vs. 5 cm for a silicone implant.
3. Cost: Silicone implants are significantly more expensive in the short and long-term than saline implants.
4. Long-term follow-up: No need for MRI scans biannually to determine if there is a silicone rupture, as recommended by FDA for silicone implants. MRI costs \$2,000–\$3,000.

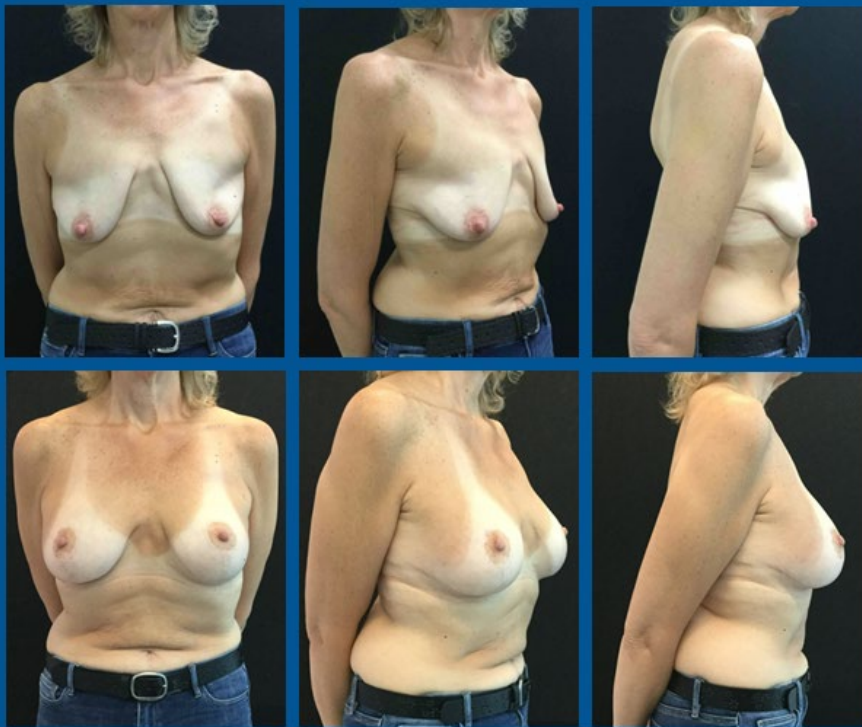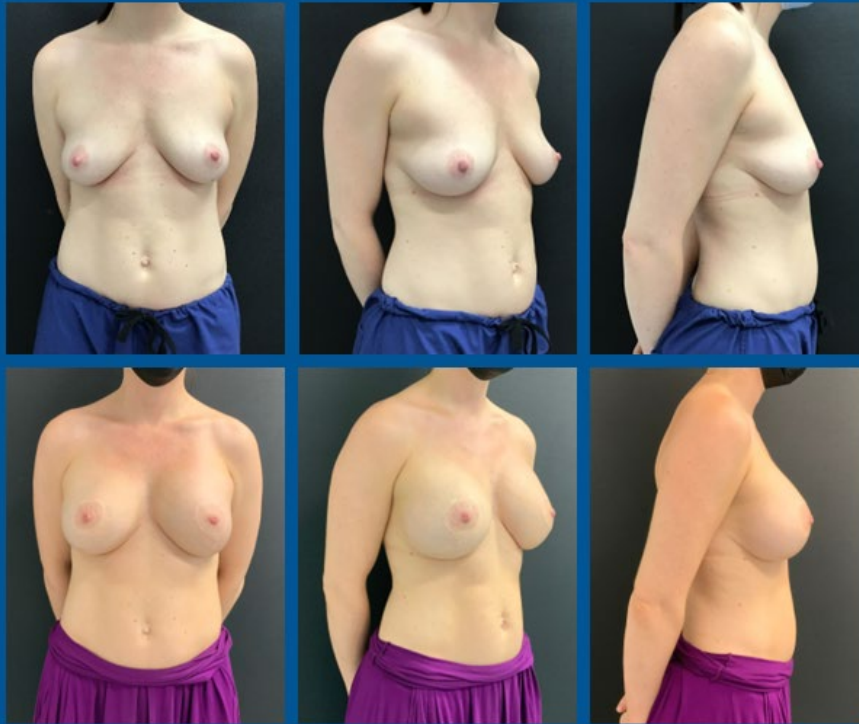## 70.12 Conclusions

The “blind” technique of transaxillary breast augmentation is a safe, effective, and simple way to perform breast augmentations. In MWL patients who frequently require a mastopexy, and would sometimes like to combine a mastopexy with an augmentation, an axillary breast augmentation/Wise pattern mastopexy provides a safe, effective, and reproducible technique which yields excellent results with low level of complications and a happy patient. Like any procedure, a learning curve is always expected, but it is truly an elegant, simple, and highly effective procedure with a minimal rate of complications.

## References

1. McNemar TB, Lomonaco J, Krieger MD. Bariatric plastic surgery: a guide to cosmetic surgery after weight loss. Omaha, NA: Addicus Books; 2008. p. 28.
2. Hurwitz D, Agha-Mohammadi S, Ota K, Unadkat J. A clinical review of total body lift surgery. *Aesthetic Surg J*. 2008; 28(3):294–303.
3. Momeni A, Padron NT, Fohn M, Bannasch H, Borges J, Ryu SM, Stark GB. Safety, complications, and satisfaction of patients undergoing submuscular breast augmentation via the inframammary and endoscopic transaxillary approach. *Aesthetic Plast Surg*. 2005;29(6):558–64.
4. Dowden R. Keeping the transumbilical breast augmentation safe. *Plast Reconstr Surg*. 2001;108(5):1389–400; discussion 1401–08.
5. Hendricks H. Complete submuscular breast augmentation: 650 cases managed using an alternative surgical technique. *Aesthetic Plast Surg*. 2007;31(2):147–53.
6. Bitar G. Breast augmentation: axillary approach. In: Shiffman MA, editor. *Breast augmentation: principles and practice*. Berlin: Springer; 2009. p. 231–40.
7. Bitar G, Myers S. Nutrition issues after bariatric surgery for weight loss (in press).
8. Hurwitz D. *Total body lift*. USA: MD Publish.com; 2005. p. 107.
9. Handel N, Cordray T, Gutierrez J, Jensen JA. A long-term study of outcomes, complications, and patient satisfaction with breast implants. *Plast Reconstr Surg*. 2006;117(3):757–67; discussion 768–72.
10. Pittet B, Montandon D, Pittet D. Infection in breast implants. *Lancet Infect Dis*. 2005;5(2):94–106.
11. FDA Breast Implant Consumer Handbook – 2004. Retrieved 30 May 2007, Web site: <http://www.fda.gov/cdrh/breastimplants/handbook2004/localcomplications.html>.
12. Troilius C. A ten-year evaluation following corrections of implant ptosis subsequent to transaxillary subpectoral breast augmentation. *Plast Reconstr Surg*. 2004;114(6):1638–41; discussion 1642–3.
13. Serra-Renom J, Garrido MF, Yoon T. Augmentation mammoplasty with anatomic soft, cohesive silicone implant using the transaxillary approach at subfascial level with endoscopic assistance. *Plast Reconstr Surg*. 2005;116(2):640–5.

# Breast Lift with Augmentation



Visit [www.bitarinstitute.com](http://www.bitarinstitute.com) for more information



BITAR COSMETIC SURGERY  
I N S T I T U T E