



# **The Efficacy of Platelet-Rich Plasma for Hair Loss: A Proven Therapy**

**George Bitar, MD, FACS**





# The Efficacy of Platelet-Rich Plasma for Hair Loss: A Proven Therapy

Vinod K. Chopra, Rana Shalhoub,  
and George J. Bitar

## Key Messages

- PRP for hair loss can aid in the treatment of androgenic alopecia
- Underlying medical conditions should be ruled out and treated
- Administering three doses of PRP spaced at about 4–6 weeks apart followed by a booster dose every 6 months is key to long lasting results
- FUE hair transplant remains the gold standard for hair restoration

## 44.1 Introduction

One of my best friends would often tell me: “Don’t tell people that I’m bald! Say that I have a shaved head. Because shaving your head is a choice, and balding isn’t.” It is quite true that hair loss is an age-old issue that has been causing angst since the dawn of time. Although baldness

was once considered an ideal characteristic of ancient roman civilization, signifying wisdom and venerability, hair loss, and thinning are now problems which can be troubling for men (up to 80%), and even women (up to 40%).

The quest for an effective cure or treatment has been an age-old problem, and the first studies for baldness were conducted in 1950 by Beek, then in 1951 by Hamilton, who detailed the classification system for hair loss. In 1975, Norwood modified Hamilton’s system for male hair loss, and in 1977 Ludwig described the classification for female hair loss [1, 2].

Platelet-rich plasma (PRP) has recently come to the forefront for treatment of hair loss and thinning. Initial applications of PRP originally began in the 1970s when hematologists used platelet-rich plasma infusions to treat thrombocytopenia. A decade later, its use evolved to a hemostatic agent in maxillofacial surgery. More recently, PRP has been used as an adjunct to improve bone graft viability and increase osseointegration via the release of growth factors. Furthermore, it has been used with success for the improvement of moderate and deep facial rhytids by inducing collagen formation by binding to mesenchymal cells and human dermal fibroblasts. Applications of PRP in the literature have been vast; however, we will focus on how we can use its regenerative abilities to combat the nuisances of hair loss.

**Supplementary Information** The online version of this chapter ([https://doi.org/10.1007/978-3-030-77455-4\\_44](https://doi.org/10.1007/978-3-030-77455-4_44)) contains supplementary material, which is available to authorized users.

V. K. Chopra (✉)  
Chantilly Cosmetic Surgery, Chantilly, VA, USA

R. Shalhoub · G. J. Bitar  
Bitar Cosmetic Surgery Institute, Fairfax, VA, USA  
e-mail: [ranashalhoub@bitarinstitute.com](mailto:ranashalhoub@bitarinstitute.com);  
[Georgebitar@bitarinstitute.com](mailto:Georgebitar@bitarinstitute.com)

## 44.2 Anatomy/Physiology of Hair Follicles

The human hair has both mesodermal and ectodermal embryologic origins. The mesoderm gives rise to the dermal papilla and the ectoderm gives rise to the hair and pilosebaceous follicle. The hair itself is made up of two portions: the shaft and the root. The shaft can be further broken down into the medulla, the cortex, and the cuticle (Fig. 44.1). The follicle anchors the hair to the skin and consists of the bulb and the bulge cells—the epicenter of hair growth and cell division. Bulge cells are multipotent hair follicle stem cells and play a pivotal role in the hair growth cycle.

The growth cycle of the hair consists of three phases: anagen, catagen, and telogen (Fig. 44.2). During the anagen phase, the hair cell is actively growing, and the keratinocytes will differentiate into the individual hair components. Approximately 90% of hair is in the anagen phase, and this stage lasts for about 2–6 years. The catagen phase is the stage in which there is regression of the hair. The keratinocytes undergo degeneration and mesenchymal cells separate. The catagen phase typically lasts about 1–2 weeks before transitioning into the resting phase, known as the telogen phase. The telogen phase is approx-

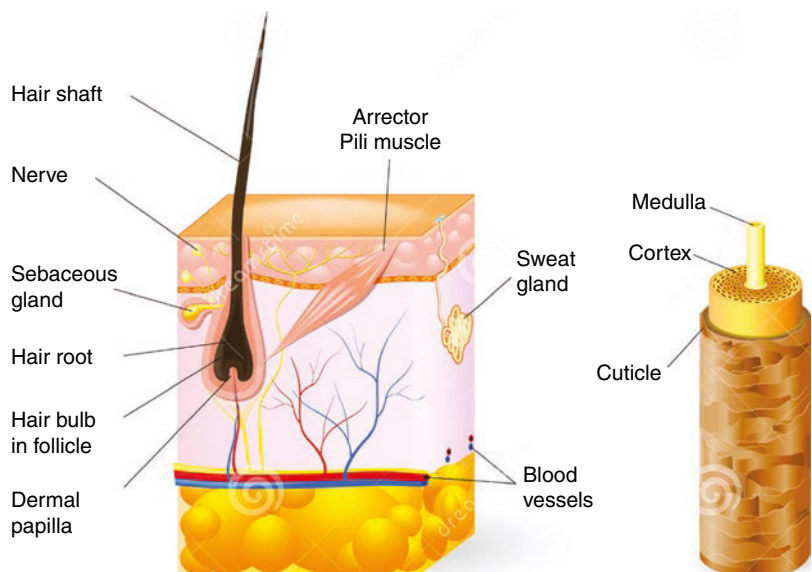
imately 5–6 weeks but can last up to 4 months. During this phase, the follicle is dormant and hair growth is paused. The hair is released from the dermal papilla, and eventually replaced by a growing hair in the anagen phase. It is important to keep in mind that a healthy head of hair can shed 80–100 hairs a day.

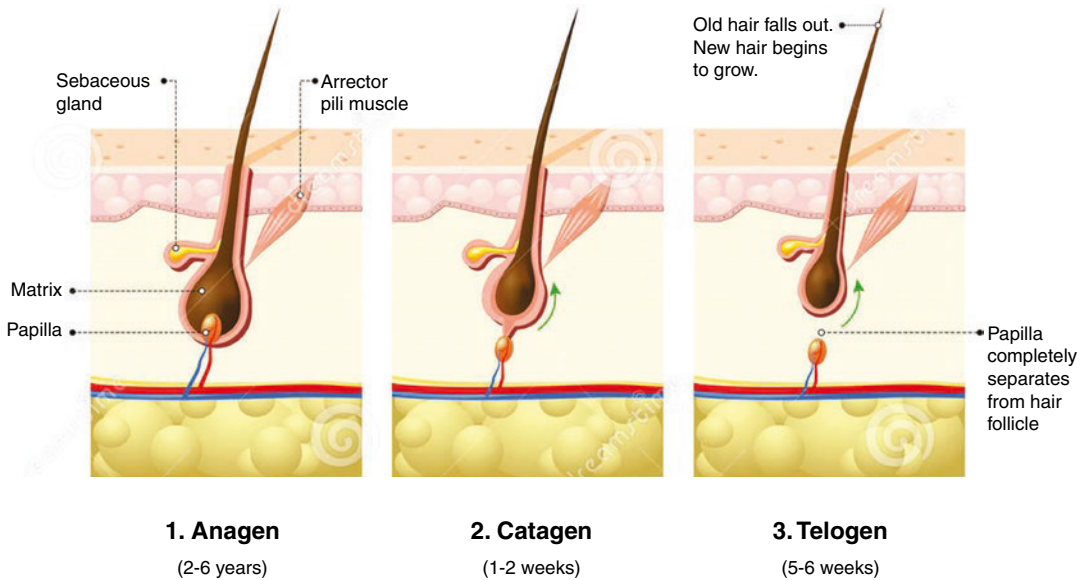
## 44.3 Factors Affecting Hair Loss

Hair loss is a multifactorial process. There are multiple causes for alopecia including androgenic alopecia, alopecia areata, nutritional deficiency, traction alopecia, scars, and burns. Because there are specific identifiable causes for alopecia areata, traction alopecia, scars, and burns, our focus will be on androgenic alopecia. In addition to the above forms of hair loss, hair loss from surgery, stress, metabolic disorders, and chemotherapy are secondary factors that can contribute to hair loss, and should also be ruled out; and deficiencies of vitamins, minerals, as well as micro- and macronutrients should be replenished [3].

The most common cause of hair loss, for both men and women, is androgenic alopecia. This type of alopecia is a response to the circulating androgens within the bloodstream at the bulb,

**Fig. 44.1** Anatomy of the human hair





**Fig. 44.2** Growth cycle of the human hair

particularly dihydrotestosterone (DHT). At the level of the hair bulb, testosterone is converted to DHT by 5  $\alpha$ -reductase, DHT then acts on the hair follicle to reduce the rate of hair growth, reduce the diameter of the hair shaft, and reduce the length of the anagen phase—eventually leading to hair loss. In men, this most commonly effects the crown and frontal area of the scalp. In women, the pattern is usually more global, but some also have hair loss similar to a male pattern. Patients with androgenic alopecia can be distressed with emotional, social, and professional issues, thus PRP can be a valuable tool in the plastic surgeon's armamentarium for combating hair loss.

#### 44.4 Background of PRP

PRP is portion of the plasma spun down from autologous blood with a concentration above baseline, ranging from 150,000 to 400,000 platelets per ul, and has now been used for a variety of applications and its use has been studied in several surgical and clinical fields. Recently, Xian et al. showed its efficacy in conjunction with autologous bone grafts for osteoradionecrosis of the femoral head [4], its application has also been seen with bone grafting for alveolar clefts. In

2015, Lauday et al. showed that PRP injections were efficacious in treating joint pain related to osteoarthritis [5]. It has also been found to be useful for the treatment of tendon injuries, regeneration of lung injuries for patients with chronic lung disease, and improvement of post-treatment erythema with laser skin resurfacing [6–8].

PRP modulates hair loss. Once platelets are introduced into the wound matrix the alpha granules release growth factors—platelet-derived growth factor (PDGF), fibroblast growth factor (FGF), transforming growth factor beta (TGF- $\beta$ ), vascular endothelial growth factor (VEGF), epidermal growth factor (EGF), and insulin-like growth factor (IGF). These growth factors then act at the stem cells within the bulge area by binding to their respective receptors and causing proliferation of the hair by transitioning the follicle from the telogen phase to the anagen phase. This differentiation of stem cells into hair follicle cells is thought to be through the upregulation of transcriptional activity of  $\beta$ -catenin. Additionally, VEGF and PDGF are thought to promote angiogenesis and enhance the perifollicular vascular plexus and improve blood supply [9].

Many protocols for PRP injections have been reported, and there are multiple variations based on physician preference. Lam advocates for a

protocol that uses 20–24 cc of PRP mixed with A-Cell immediately after the grafts have been implanted. The most effective protocols call for the use of three injections spaced 21 days apart with a single booster dose at 6 months. Hair density increased by 7.0%, and there was an average patient satisfaction of 7.1/10. Additionally, hair density reached its peak at 3 months post treatment: 143 hair/cm<sup>2</sup> vs 170 hair/cm<sup>2</sup>. Results also showed there was no difference in the treatment results between males and females for the treatment of androgenic alopecia [9, 10]. Some studies have shown no difference between baseline and post treatment, the key factors in these studies are that patients received less than three injections of PRP, and thus a total of three injections plus maintenance may be the key to achieving successful results [11–13].

The earliest studies of PRP for hair growth date back to 2012, and mostly show positive results for restoration of hair [9, 10, 14–16]. However, within these studies there is a lack of uniformity regarding the timing of injections, administration of a booster dose, and lack of standardized methods to quantify results. In addition to this, sample sizes have been limited, as the largest study consisted of 20 patients.

---

#### **44.5 Indications, Contraindications, Limitations, and Complications**

According to Alves and Grimalt, ideal candidates for treatment are males with androgenic alopecia who are ideally younger than 40 years old, started to lose hair after the age of 25, and have had evolution of their hair loss for at least 10 years [17, 18]. That being stated, we do have patients who are over that age range who would still want to undergo PRP treatment. Patients should also still have active hair follicles within the target area. Contraindications for injection include the following: thrombocytopenia, platelet dysfunction, hemodynamic instability, bleeding diathesis, acute or chronic infections of the scalp, hepatitis, and anti-coagulation. If patients are on aspirin or

NSAID therapy, they should stop taking their medications for 7–10 days prior to treatment. PRP therapy has its limitations:

1. It may rarely increase numbers of hair but mostly strengthens and nourishes existing hair and makes them thicker.
2. It benefits the patient for months or even years but may need to be repeated after 2 years optimally if the patient does not agree to 6-months booster doses.
3. It is expensive due to the technology and highly skilled labor to perform it.

The most common complications and side effects are mild pain or bleeding at the injection site, temporary scalp tenderness, swelling, itching, creation of scar tissue, and headache.

---

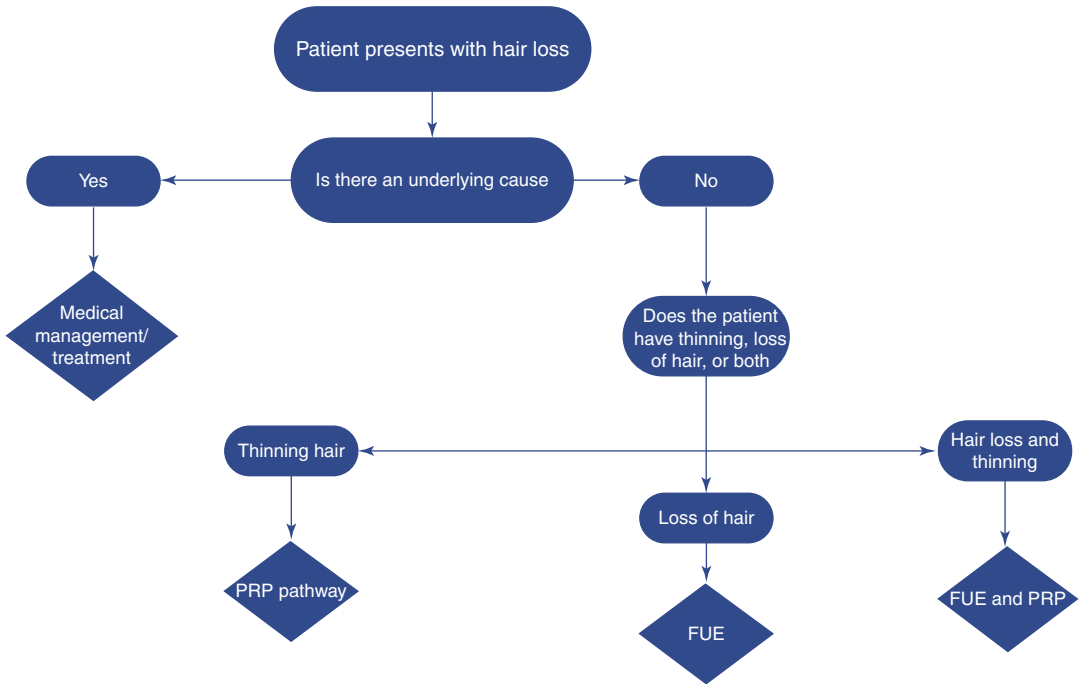
#### **44.6 Our Algorithm for PRP Patient Selection**

Below is our practice's algorithm (Fig. 44.3) for the patient that presents with hair loss. If there is an underlying medical cause for hair loss, this should be worked up, and the patient should undergo medical therapy. Patients who have thinning hair are candidates for treatment with PRP, but patients with complete hair loss in a certain area are candidates for hair transplant. We have combined hair transplantation in the form of follicular unit extraction (FUE) with PRP treatment successfully for patients with both hair loss and hair and thinning.

---

#### **44.7 Our PRP Injection Protocol**

Designing a protocol for PRP is not without frustration. Because of the difficulty of designing a control group, there is much heterogeneity in the literature between various protocols, adjuvant therapies, measuring of outcomes, and long-term follow-up—which tends to be limited. Also, there is much variability in the preparation of the PRP, and there is no standardized concentration of platelets used. Number of treatments and interval



**Fig. 44.3** Algorithm for patient selection with PRP

of injections also have not been standardized or compared. Our protocol for PRP injections uses three injections spaced approximately 4–6 weeks apart followed by one maintenance treatment every 6 months.

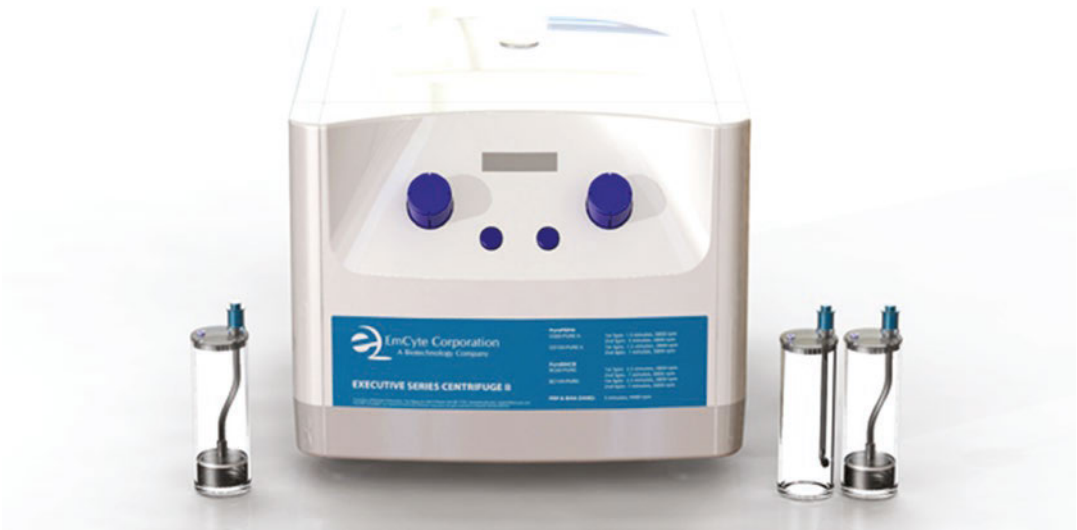#### 44.8 How to Obtain and Process PRP

In our practice, 30–60 cc of whole blood is drawn, based upon the area to be treated, and then centrifuged using EmCyte Executive Series II (Fig. 44.4). If 30 cc of whole blood is used, then this is spun at 4200 rpm  $\times$  1.5 min. The platelet layer is then isolated and spun for additional 5.5 min at 4200 rpm. If 60 cc of whole blood is required, the same protocol is used with a 3800 rpm speed. After the second spin, the supernatant, which is the platelet poor plasma, is discarded and the PRP is then isolated at the bottom

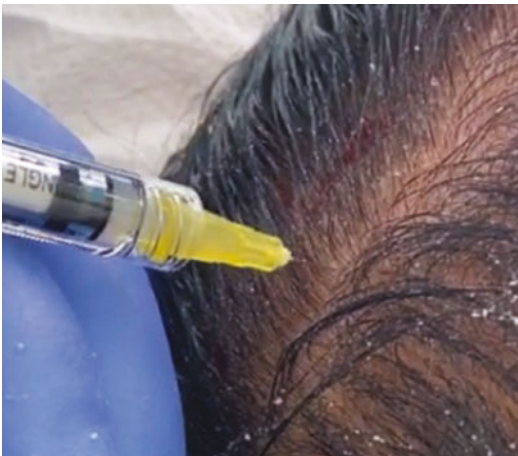of the tube. Every 30 cc of whole blood will provide approximately 7–10 cc of PRP. We then draw this into 1 cc syringes and use 30 g needles in preparation for injection.

#### 44.9 Injection technique

The area of the scalp to be treated is anesthetized using topical anesthesia with BLT (Benzocaine Lidocaine, Tetracaine) Cream, a ring block of the scalp is also performed with lidocaine, and self-administered nitrous oxide (PRO-NOX™) can also be used if the patient desires. The scalp is then cleansed with 4% chlorhexidine gluconate, and the syringe is then introduced into the scalp of the treatment area at a 45-degree angle, at a depth of approximately 2.0–2.5 mm. 0.1 cc of PRP is then injected and the process is repeated at 1 cm intervals, forming a grid-like pattern (Fig. 44.5, Videos 44.1 and 44.2).



**Fig. 44.4** EmCyte Pure PRP system



**Fig. 44.5** Injection technique of PRP to the scalp

## 44.10 Results

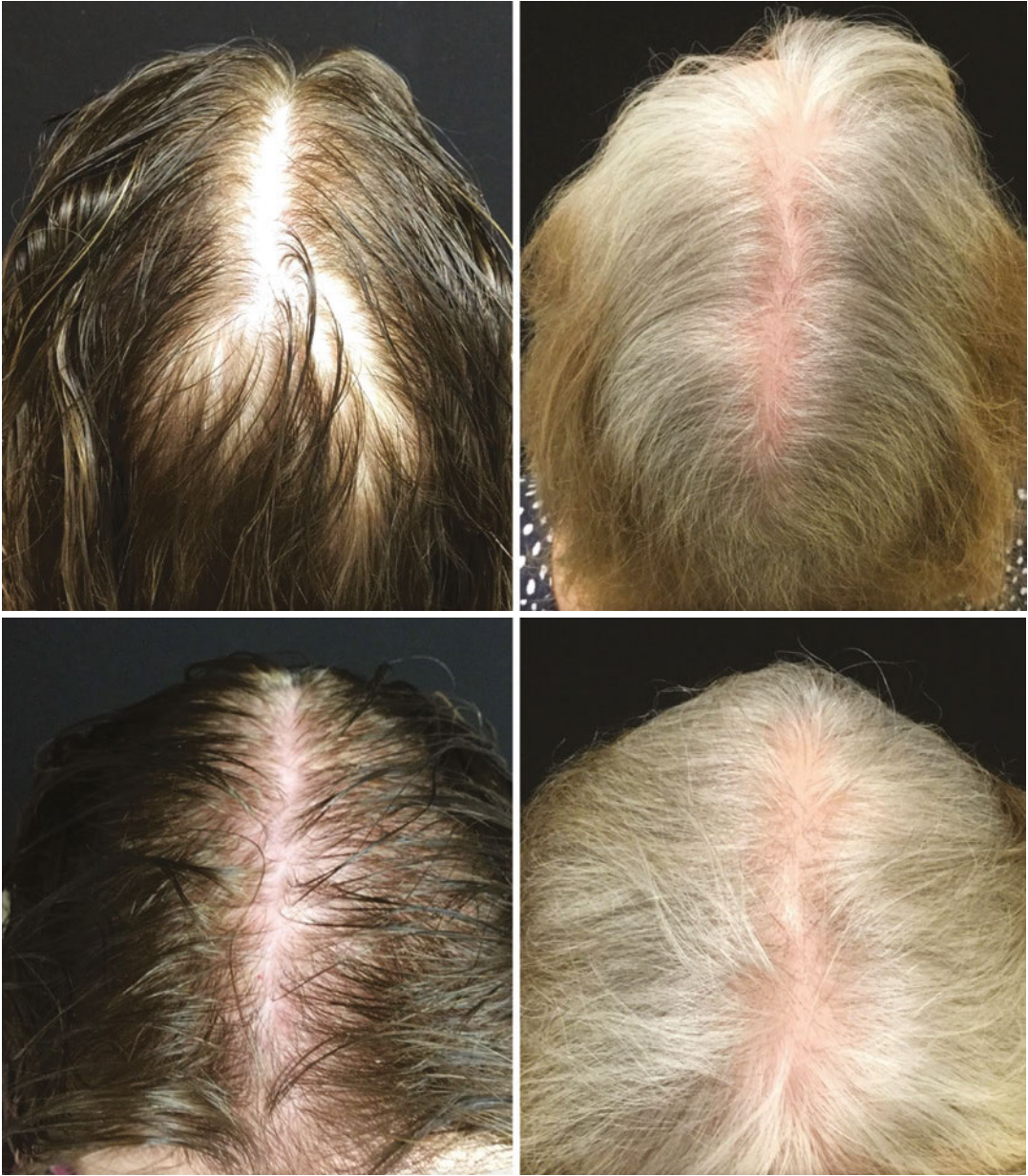
We reviewed the charts of 20 patients in our practice that underwent PRP injections for hair loss from June 2015 to October 2020. Our sample size was  $n = 20$  with an age distribution between 22 and 70 years of age and an average age of 46.3 years. Patients consisted of 5 males (25%) and 15 females (75%). Each patient received 1–4 treatments spaced at 4–6-week intervals with an

**Table 44.1** Characteristics of our PRP population

Patient characteristics	
Number of patients	20
Age range	22–70
Average age	46.3
Male sex	25%
Female sex	75%
Average treatments	2.6

average of 2.6 treatments per patient, with a total of 51 treatments (Table 44.1). Before and after photos were reviewed by a plastic surgeon who was blinded to the patients to determine if there was improvement. The patients who had completed their PRP treatments did have a noticeable improvement with comparison of before and after photos. Results ranged from stopping the progression of hair loss to thicker and more robust existing hairs. In our experience, patients ranged from satisfied to very satisfied with results at 6, and 12 months follow-up intervals, and no serious adverse events were noted. There were two patients who complained about pain during injections earlier in our protocol before starting our optional PRO-NOX™ treatment. One additional patient had itching that subsided after a few days with Benadryl (Figs. 44.6, 44.7, 44.8).



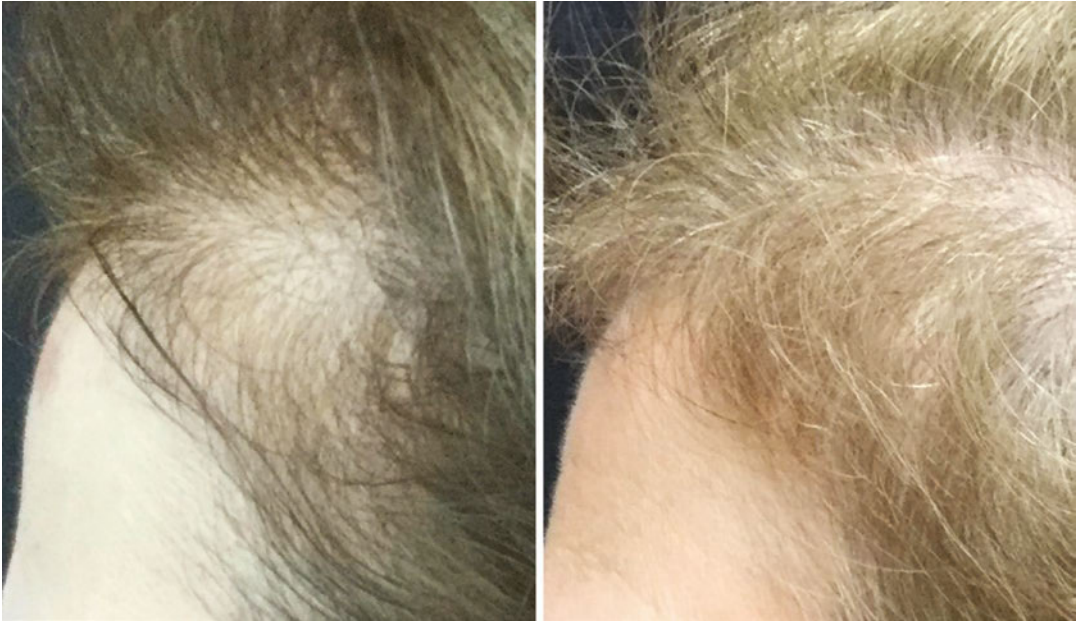

**Fig. 44.6** 68-year-old female 3 months status-post 3 rounds of PRP injections to the scalp

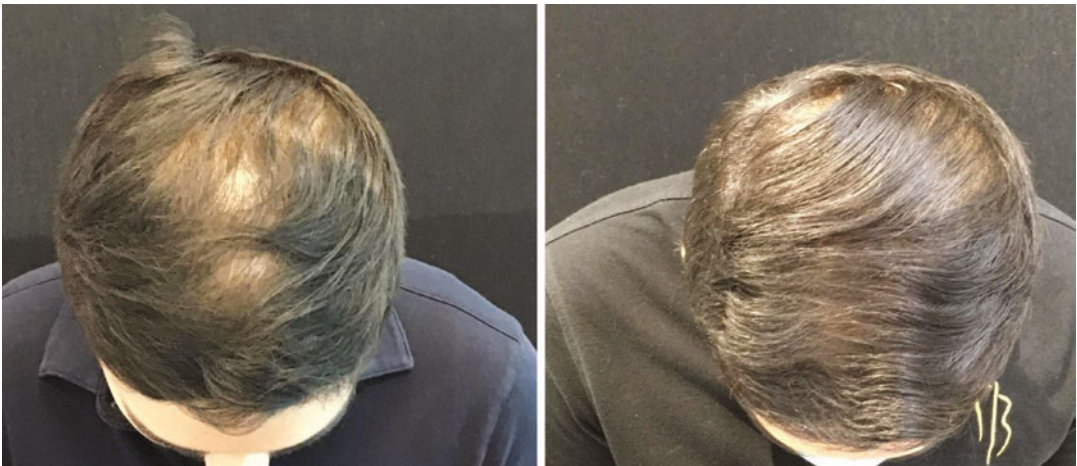### 44.11 Conclusion

Androgenic alopecia can be a very distressing problem for patients, and the disease process can affect both men and women. PRP for hair loss offers a minimally invasive, non-surgical option for patients who may be unwilling to or unable to undergo hair transplant surgery. In our surgical

practice, the average age of our patient population is 39.6 years. This may point towards a trend of treating, or combating, hair loss, and thinning at an earlier age. In our practice, women outnumber men in the use of PRP for hair loss (75% vs 25%). This is attributable to the fact that most of the men in our practice elect to undergo follicular unit extraction (FUE) hair transplant as opposed



**Fig. 44.7** 56-year-old female 1-month status-post 3 rounds of PRP injections to the scalp

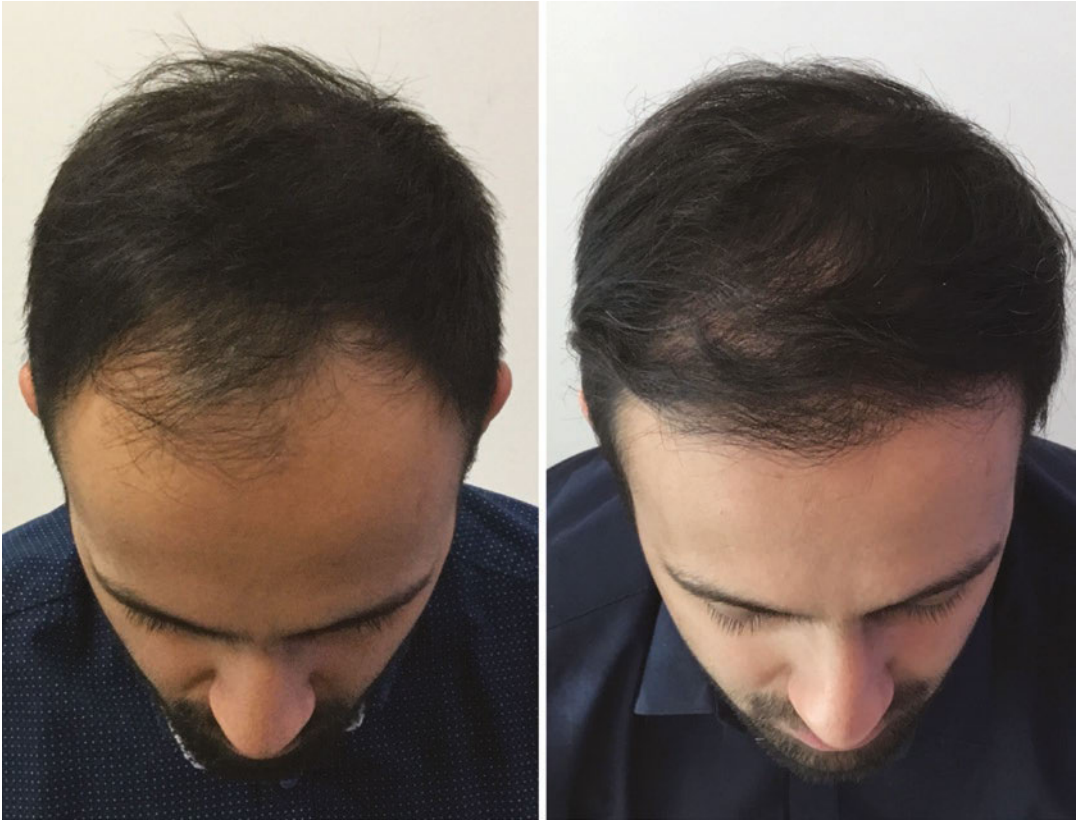

**Fig. 44.8** 25-year-old male 1-year status-post 1 round of PRP injections to the scalp

to PRP (Fig. 44.9). While efficacy tends to vary in clinical studies, the risk of PRP injections is minimal. Our practice has experienced favorable results, and we have not had any serious adverse outcomes from injecting PRP, which is in line with the low complication rate in the literature. Limitations of PRP injections include the fact that benefits may only be temporary without ongoing booster injections, the improvement of

hair density is not as profound as FUE hair transplant, and there is great variability between different injectors.

While PRP therapy has been shown to have favorable results, there are still many adjunctive therapies that should be taken into consideration. Minoxidil and Finasteride have yielded good results in the past; however, a recent half-head controlled study has shown that PRP with topical



**Fig. 44.9** 31-year-old male 1-year status-post FUE hair transplant

minoxidil was superior to combination with oral finasteride [19]. In addition to minoxidil, microneedling has also been shown to be a useful adjuvant therapy. Studies have shown that microneedling in addition to minoxidil showed improvement over minoxidil alone [20]. On the forefront of combination therapy is currently the use of PRP with A-Cell. Although no formal studies exist, reports have shown promising results for hair restoration.

Additionally, the use of PRP in hair transplant should also be considered. In 2006, Ubel et al. advocated using the bathing of follicular units in PRP prior to implantation and showed a 15% increase in take density [16]. This process causes proliferation of the cells within the dermal papilla by upregulating FGF-7 [21]. Additionally, there may be a role for bathing the follicular units in platelet poor plasma prior to implementation. Its

use for this has been described; however, studies have yet to investigate its role.

The future of PRP as a treatment modality is still being investigated. Researchers have been studying its use as a combination therapy with Dalteparin microparticles as a carrier, as well as in combination with Finasteride and Minoxidil. Furthermore, it is also being studied in conjunction with cell-based therapies [22]. Further areas for investigation would also include criterion to determine which patients will have the best response to PRP. Although criteria for ideal candidates have been described in the literature, currently there are no studies that allow us to predict who will be a responder to PRP.

By using the inflammatory and prothrombotic pathway to our advantage, clinicians have been able to target the appropriate growth fac-

tors to stimulate follicular cells into the anagen phase. Furthermore, because patients are injected with autologous blood product, the possibility of reaction is obviated. There have been many protocols developed since the initial PRP studies used on follicular transplant in 2006. Protocols that incorporate the use of A-cell aside, most advocate for the use of injections at approximately 1-month intervals with a booster at 6 months. Our protocol advocated for a booster dose every 6 months after the first three injections. Our experience suggests that PRP injections are a reliable, safe, and effective treatment modality that has provided patients with high satisfaction as a treatment for hair loss.

## References

- Gupta M, Mysore V. Classifications of patterned hair loss: a review. *J Cutan Aesthet Surg*. 2016;9:3–12.
- Wirya CT, Wu W, Wu K. Classification of male-pattern hair loss. *Int J Trichology*. 2017;9:95–100.
- Almohanna HM, Ahmed AA, Tsatalis JP, Tosti A. The role of vitamins and minerals in hair loss: a review. *Dermatol Ther (Heidelb)*. 2019;9(1):51–70.
- Xian H, Luo D, Wang L, et al. Platelet-rich plasma-incorporated autologous granular bone grafts improve outcomes of post-traumatic osteonecrosis of the femoral head. *J Arthroplasty*. 2019;
- Laudy AB, Bakker EW, Rekers M, Moen MH. Efficacy of platelet-rich plasma injections in osteoarthritis of the knee: a systematic review and meta-analysis. *Br J Sports Med*. 2015;49(10):657–72.
- Kim H, Gallo J. Evaluation of the effect of platelet-rich plasma on recovery after ablative fractional photothermolysis. *JAMA Facial Plast Surg*. 2019;17(2):97–102.
- Mammoto T, Chen Z, Jiang A, Jiang E, Ingber DE, Mammoto A. Acceleration of lung regeneration by platelet-rich plasma extract through the low-density lipoprotein receptor-related protein 5–tie2 pathway. *Am J Respir Cell Mol Biol*. 2016;54(1):103–13.
- Zhang J, Middleton KK, Fu FH, Im HJ, Wang JH. HGF mediates the anti-inflammatory effects of PRP on injured tendons. *PLoS One*. 2013;8(6):e67303.
- Gkini MA, Kouskoukis AE, Tripsianis G, Rigopoulos D, Kouskoukis K. Study of platelet-rich plasma injections in the treatment of androgenetic alopecia through an one-year period. *J Cutan Aesthet Surg*. 2014;7:213–9.
- Maria-Angeliki G, Alexandros-Efstratios K, Dimitris R, Konstantinos K. Platelet-rich plasma as a potential treatment for noncicatrical alopecias. *Int J Trichology*. 2015;7(2):54–63.
- Badran KW, Sand JP. Platelet-rich plasma for hair loss: review of methods and results. *Facial Plast Surg Clin North Am*. 2018;26(4):469–85.
- Giordano S, Romeo M, Lankinen P. Platelet-rich plasma for androgenetic alopecia: Does it work? Evidence from meta analysis. *J Cosmet Dermatol*. 2017;16(3):374–81.
- Puig C, Reese R, Peters M. Double-blind, placebo-controlled pilot study on the use of platelet-rich plasma in women with female androgenetic alopecia. *Dermatol Surg*. 2019;42(11):1243–7.
- Li ZJ, Choi HI, Choi DK, et al. Autologous platelet-rich plasma: a potential therapeutic tool for promoting hair growth. *Dermatol Surg*. 2012;38(7 Pt 1):1040–6.
- Singhal P, Agarwal S, Dhot PS, Sayal SK. Efficacy of platelet-rich plasma in treatment of androgenic alopecia. *Asian J Transfus Sci*. 2015;9(2):159–62.
- Uebel CO, da Silva JB, Cantarelli D, Martins P. The role of platelet plasma growth factors in male pattern baldness surgery. *Plast Reconstr Surg*. 2006;118(6):1458–66; discussion 1467.
- Alves R, Grimalt R. Randomized placebo-controlled, double-blind, half-head study to assess the efficacy of platelet-rich plasma on the treatment of androgenetic alopecia. *Dermatol Surg*. 2016;42(4):491–7.
- Alves R, Grimalt R. A review of platelet-rich plasma: history, biology, mechanism of action, and classification. *Skin Appendage Disord*. 2018;4(1):18–24.
- Alves R, Grimalt R. Platelet-rich plasma in combination with 5% minoxidil topical solution and 1 mg oral finasteride for the treatment of androgenetic alopecia: a randomized placebo-controlled, double-blind, half-head study. *Dermatol Surg*. 2018;44(1):126–30.
- Kumar MK, Inamadar AC, Palit A. A randomized controlled, single-observer blinded study to determine the efficacy of topical minoxidil plus microneedling versus topical minoxidil alone in the treatment of androgenetic alopecia. *J Cutan Aesthet Surg*. 2018;11(4):211–6.
- Gentile P, Garcovich S, Bielli A, Scioli MG, Orlandi A, Cervelli V. The effect of platelet-rich plasma in hair regrowth: a randomized placebo-controlled trial. *Stem Cells Transl Med*. 2015;4:1317–23.
- Anitua E, Pino A, Jaen P, Navarro MR. Platelet rich plasma for the management of hair loss: better alone or in combination? *J Cosmet Dermatol*. 2019;18(2):483–6.



Bitar Cosmetic Surgery Institute & Medspa  
3023 Hamaker Court  
Suites 109 & 114  
Fairfax, VA 22031



BITAR COSMETIC SURGERY  
I N S T I T U T E