


Modern Plastic Surgery, Lasers, and Skin Care 703.206.0506

 BITAR  
COSMETIC SURGERY INSTITUTE

Home | Dr. Bitar | About Us | Events | Media | Specialties | Non Surgical | Gallery | Fees | Contact Us

## Plastic Surgery Products Magazine, October 2007 Issue

### Breast Augmentation: The Axillary Approach

by George John Bitar, MD, and Vinod K. Chopra

This breast-augmentation technique performed using saline implants and a blind approach instead of endoscopy is controversial, but its results are excellent



There is no such thing as the perfect breast-augmentation technique, so opinions differ (and debates are heated) among plastic surgeons about the best way to perform this procedure. We believe that transaxillary submuscular breast augmentation, performed using saline implants and a blind dissection technique without endoscopy, is a simple procedure associated with a high level of satisfaction and a low rate of complications.

The literature<sup>1-3</sup> compares various techniques for breast-implant placement in the submuscular or subglandular planes; the use of silicone or saline implants; and transaxillary, transumbilical, inframammary, or periareolar incisions. Within each technique, there are myriad nuances and variations among surgeons, who must choose an operation that works well in their hands, makes the patient happy, and has a relatively low complication rate.

#### Initial Consultation

It is important for the patient to understand what breast augmentation will accomplish for her. Limitations, risks, benefits, and postoperative expectations should be discussed in detail. Since the patient will have a long-term prosthesis, it is of paramount importance to discuss long-term consequences.

The main indications for breast augmentation are hypomastia and breast asymmetry. The decision to have breast augmentation should be explored in the initial consultation. The patient's answer to, "Why do you want to have breast augmentation?" can be very telling. Reasons stated by women seeking breast augmentation have varied tremendously.

Typically, a woman who is having the procedure to enhance her own self-image (without concern for external forces) will have the highest likelihood of success and happiness with the operation. Furthermore, she will be in the best position to handle a complication appropriately, should there be one.

During the initial consultation, the patient is asked to place silicone breast implants of a known size in her bra

and to wear a shirt that reveals her silhouette clearly. The patient tries on implants of different sizes until she finds the size that she likes.

We offer our patients the option of trying on various sizes again on the second consultation. Usually, they choose either the same size or a size similar to the one chosen at the initial consultation. We encourage patients to choose implant sizes within the range of 150 to 400 mL, with exceptions for certain situations.

### Preoperative Workup

The patient should obtain routine medical clearance, along with psychiatric clearance (if needed). Medications that can interfere with a good outcome, such as those that increase the likelihood of bleeding, should be discontinued before surgery. A pregnancy test should be ordered preoperatively for a woman in her childbearing years.

A complete blood count and international normalized ratio will provide a general idea of the patient's hematological state. Urinalysis is also important, since ongoing infection may warrant treatment before prosthesis insertion.

A mammogram should be obtained by a woman whose level of risk of breast cancer is considered high, based on the recommendations of the American Cancer Society. To improve the surgical outcome, the patient should stop smoking for at least 2 weeks before and after the operation.

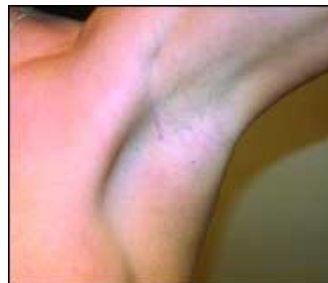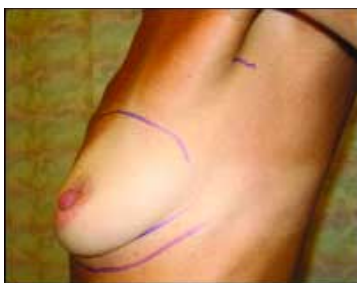Two specific circumstances call for additional steps. If a woman seeking breast augmentation is planning to become pregnant shortly after the procedure, she should understand that pregnancy can create changes in breast shape and size. There is a small chance that a breast-augmentation operation will have complications that could render a woman unable to breast-feed.

A future operation to change the size of the breast implant, remove it, or perform mastopexy may be warranted, and the patient should be well aware of these possibilities. It is also important to address any history of breast cancer in the patient or her family. Whether the implants are silicone or saline, and whether their placement is submuscular or subglandular, breast-cancer detection should be discussed with the patient.

### Marking and Preparation

The patient is marked while she is standing. The inframammary folds, the superior border of where the implant should lie, and the midline are marked. A 2-cm line is drawn at the lower aspect of the hair-bearing area of the axilla (Figure 1).

#### Before & After



**Figure 1.** The marked area of the axilla is where the incision is made (left), leaving a virtually imperceptible scar (right).

After the patient has been anesthetized and intubated, the breasts are infiltrated with tumescent solution (in a fashion similar to that used for liposuction). The injection technique is important to the achievement of hydrodissection in the submuscular plane and vasoconstriction of the area to be dissected.

Pneumothorax is much less likely if the surgeon lifts the breast with the nondominant hand and injects the tumescent fluid with the dominant hand, parallel to the rib cage in the submuscular plane. While the tumescent fluid is allowed to take effect, the patient is prepared for surgery in the usual sterile fashion from the neck to below the umbilicus (including the axillae).

### **Surgical Technique**

After the tumescent solution takes effect, a 2-cm incision is made in the lower pole of the hair-bearing area of the axilla. Using a pair of curved Mayo scissors, a pocket is created in the axilla.

Next, digital dissection is carried out to establish an intermuscular plane between the pectoralis major and minor muscles. Care is taken to avoid trauma to vessels and musculature; however, the tumescent solution helps to minimize bleeding so much that electrocautery is seldom used with this technique. It is an almost bloodless procedure.

When the intermuscular plane has been established, a blunt, curved dissector (such as a Van Buren sound or uterine sound) is used to complete the subpectoral pocket. After the submuscular pocket has been created, implant sizers are inserted through the axillary incision and are filled to the size on which the patient and the surgeon have agreed. The back of the table is then elevated so that the patient can be assessed in a sitting position.

Adjustments can be made using finger dissection or blunt-sound dissection until the surgeon is satisfied with the size and shape of the augmented breasts. This is probably the step where experience helps most.

Medially, the muscle should be elevated enough to create nice cleavage, but not so much as to create symmastia. Inferiorly, insufficient dissection may lead to a high-riding implant, but aggressive dissection may lead to a double-bubble sign. Laterally, the breast should have a nice fullness, but if the dissection is too aggressive, the patient will complain that, when she lies down, the implant ends up in the axilla.

Proper dissection of the breast pocket may initially be learned using direct visualization with endoscopic guidance. Once the surgeon feels comfortable with the boundaries of the dissection, however, we believe that a blind technique is less costly, is more efficient, is simpler, and produces results that are at least comparable.

During the next phase of surgery, one sizer implant is removed, the surgeon changes gloves, the axillary incision site is cleaned with povidone-iodine solution, and the assistant puts an Army-Navy retractor in place to open the pocket for the surgeon. The surgeon empties the air from the saline implant, rolls it, and inserts it through the incision without letting it touch the skin (with the valve facing anteriorly). When the implant has been completely inserted, it is filled with the desired amount of saline using a closed system and a one-way stopcock to ensure the sterility of the saline.

The sizer in the contralateral breast is kept in place to ensure hemostasis until it is time to place the implant on that side. The sizer is then removed and the saline implant is placed. Next, the implants and general shape of the breasts are inspected with the patient sitting.

When the shape and size are deemed appropriate by the surgeon, the filling tubes are removed. The incisions are closed using 3.0 polyglactin 910 interrupted sutures for the dermis, and a 4.0 polyglactin 910 subcuticular closure is performed.

### **Postoperative Care**

The incisions are covered with flexible skin-closure strips, and foam tape is placed around the breasts to ensure healing in the proper position. A bra is put on the patient, and dressings are used to cover the axillary incisions. The patient recovers in the ambulatory surgery center or hospital for 1 to 2 hours and is given an antiemetic, if needed.

The patient is asked to sleep supine, with her head elevated, and to take the appropriate antibiotic and

analgesic medications. The patient is seen the following day, and the incisions (as well as the overall appearance of the patient and the breasts) are inspected. Any early problems are addressed promptly.

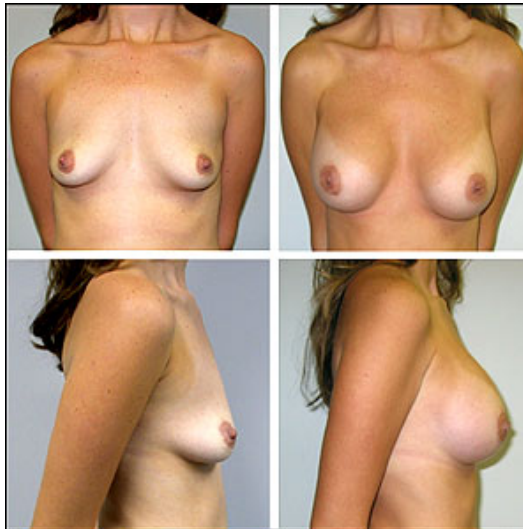
Most patients heal uneventfully, with minimal ecchymosis and minimal-to-moderate edema. The tape is removed after a week, and a breast binder is applied to achieve pressure and expedite the settling of the implants. Daily activity is resumed after a few days, work can be resumed in about a week, and exercise can be resumed after the third week, in most cases.

## Results

Patients who have undergone this procedure in the senior author's practice have ranged in age from 17 to 66 years old. Some have had simultaneous procedures such as mastopexy, liposuction, abdominoplasty, or facial rejuvenation. The overall satisfaction rate has been very high, with a very low rate of complications.

With this technique, pain has been limited to the first few days after surgery and has been controlled using analgesic medications. Complications have been limited to hematoma (less than 1%), capsular contracture (1%), deep-vein thrombosis (less than 1%), implant deflation (less than 1%), and dissatisfaction due to asymmetry (a few cases). There were no implant infections, high-riding implants, double-bubble signs, pneumothoraces, cases of inability to breast-feed, permanent losses of nipple sensation, major medical complications, or deaths.

### Before & After



**Figure 2. Results of the transaxillary breast-augmentation procedure.**

## Discussion

Performing transaxillary breast augmentations using a blind approach instead of endoscopy is controversial, but the results of the blind approach are excellent (Figure 2). The critics' view that this technique will yield high-riding implants has not been true of cases in the senior author's practice.

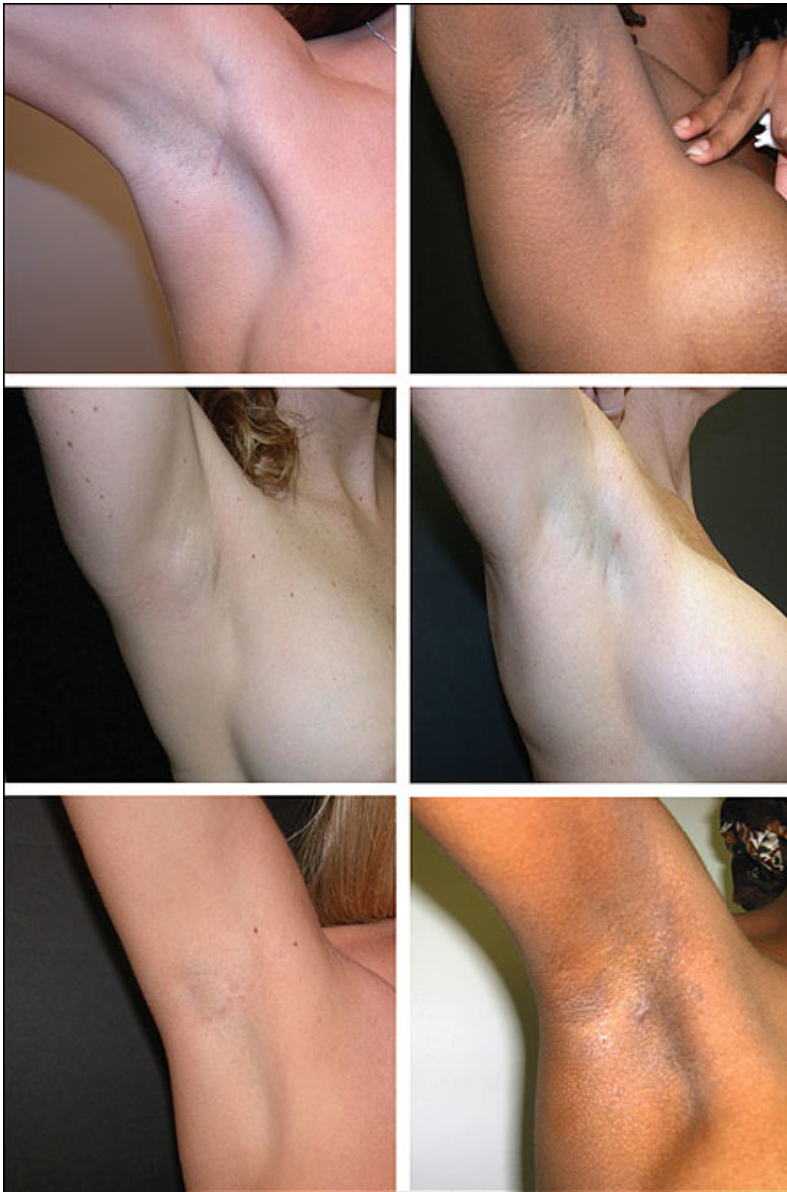One advantage of this technique over the endoscopically assisted technique is the shorter operating time. The actual surgical time is 25 to 40 minutes, which is significantly less than the endoscopic approach requires. Other advantages are the elimination of reliance on endoscopic equipment, the lower cost without endoscopy, and the avoidance of added variables in an operation that is otherwise simple.

The chosen implant type affects the type of surgery to be performed. It is difficult to perform a silicone breast augmentation using an axillary approach. The incision must be 5 cm long for a silicone implant,<sup>4</sup> not the 2 cm needed for a saline implant. The technique described here applies only to saline implants inserted through axillary incisions.

Silicone implants are advantageous in certain situations. Silicone breast implants feel more natural than saline implants if the patient has undergone many breast procedures and has little breast tissue or muscle remaining. Silicone implants may also be preferable when a woman is very thin, in which case they may feel more natural. In these two situations, patients are offered silicone breast augmentation.

That, however, is where the advantages of silicone implants end, in the senior author's opinion. If a woman's breast size is at least a small B cup and the saline implants are submuscular, the feel of the breast is very

natural, making the argument that silicone implants feel more natural an invalid reason for having silicone implants.



*Figure 3. Axillary scars in women of various skin colors.*

#### **Why Saline Implants Are Favored**

- **Safety:** Saline implants are safe. If they rupture, saline is spilled; as opposed to silicone, which may cause local silicone granuloma, eggshell-like calcification, or hardening of the breast.
- **Scar location:** Saline implants are more easily inserted from transaxillary incisions.
- **Scar length:** The scar is about 2 cm long for saline, versus 5 cm long for silicone.
- **Cost:** Silicone implants are significantly more expensive, over both the short and long terms, than saline implants.
- **Long-term follow-up:** Biennial MRI scans are recommended by the FDA for patients with silicone implants to detect implant rupture; this need does not apply to patients with saline implants.

#### **Advantages and Disadvantages**

The scar for saline augmentation is about 2 cm long and heals inconspicuously, appearing to be an axillary crease (Figure 3). The implant can be inserted subpectorally with minimal muscle dissection, so the muscle is minimally manipulated. This yields many advantages: shorter intraoperative time; minimal bleeding; less trauma, scarring, pain, and bruising; and a shorter recovery time with minimal complications.

The milk ducts are not manipulated, so the risk of losing the ability to breast-feed after this approach is negligible. The breast tissue is not dissected, so there is no additional scarring that may affect mammogram interpretation.

The scar is relatively distant from the implant, so if there is a superficial scar infection, the implant is well protected. There is also a lower probability of injuring the fourth intercostal nerve that supplies sensation to the nipple.

There are, however, three possible disadvantages of the approach described here. The scar, although small, can be evident in the axilla the first few months before it heals completely and fades, but it will never completely disappear. It is difficult to remove an implant from an axillary incision in the future if a revision is needed, so another approach may be used at that time. There is also the possibility of loss of sensation in a small area of the axilla if the costobrachial nerve is injured.

The blind technique of transaxillary breast augmentation is safe, effective, and simple, with clear advantages over other ways of performing breast augmentations. As for any procedure, a learning period is to be expected, but this is truly an elegant, simple, and highly effective procedure with a minimal rate of complications.

*George John Bitar, MD, is a board-certified plastic surgeon in private practice in northern Virginia. He is on staff at INOVA Fairfax Hospital in Falls Church and Prince William Hospital in Manassas. He can be reached at (703) 206-0506 or via his Web site, [www.drbitar.com](http://www.drbitar.com).*

*Vinod K. Chopra is a medical student, George Washington University School of Medicine and Health Sciences, Washington, DC.*

## References

1. Momeni A, Padron NT, Föhn M, et al. Safety, complications, and satisfaction of patients undergoing submuscular breast augmentation via the inframammary and endoscopic transaxillary approach. *Aesthetic Plast Surg.* 2005;29:558-564.
2. Dowden R. Keeping the transumbilical breast augmentation safe. *Plast Reconstr Surg.* 2001;108:1389-400,1401-1408.
3. Hendricks H. Complete submuscular breast augmentation: 650 cases managed using an alternative surgical technique. *Aesthetic Plast Surg.* 2007;31:147-153.
4. Serra-Renom J, Garrido MF, Yoon T. Augmentation mammoplasty with anatomic soft, cohesive silicone implant using the transaxillary approach at subfascial level with endoscopic assistance. *Plast Reconstr Surg.* 2005;116:640-645

Home | Meet Dr. Bitar | About Us | News & Events | Specialties | Medispa | Gallery | Contact Us  
Bitar Cosmetic Surgery Institute, 3023 Hamaker Court. # 109 Fairfax, VA. 22031 · Phone: 703.206.0506  
© 2007 Bitar Cosmetic Surgery Institute , All rights reserved | Web Design by Blue Water Media

